

# Cervical Spine Injuries in the Athlete

David Chang, M.D., and Joseph A. Bosco, III, M.D.

Spinal pain, while common in the general population, is essentially universal in the athletic population. Certain specific positions and activities of a given sport inherently place athletes at a high risk for the development of low back or neck pain syndromes. As an example, “stingers” occur more commonly in wrestlers, particularly with the take-down maneuver, and as well in football players, especially for defensive backs and offensive linemen. Although low back and neck pain syndromes can be trauma related, this review will focus on the epidemiology, anatomy, prehospital care, imaging, prevention, and rehabilitation of the many types of cervical spine trauma commonly seen in athletes (Table 1) and will not cover complex cervical spine fractures.

## Epidemiology

The vast majority of spinal cord injuries (SCIs) in athletes involve the cervical spine. Ghiselli and colleagues reported that the incidence of cervical spine injuries in sports is 1000 per year, mostly from diving and swimming (hitting the bottom of the pool).<sup>1</sup> This is consistent with Maroon and Bailes, who note that cervical spine injuries in the athlete account for 10% of the 10,000 cervical spine injuries per year in the U.S.<sup>2</sup> Many of these are incomplete injuries, meaning that some neurologic function is preserved. High risk sports and team positions associated with sustaining a

cervical cord injury include, but are not limited to, football (defensive player/tackling), gymnastics (dismounting), soccer (goalie), and ice hockey (being checked from behind or hitting the boards headfirst). The overall incidence of spinal cord injury in high school and college athletes has been estimated to be 1/100,000 participants per year. In 1976, the incidence of complete quadriplegia was 2.5/100,000, which has subsequently decreased to 0.5/100,000 in 1991.<sup>3</sup> By these numbers, the incidence may seem low, but given the millions of young athletes competing in sports, a substantial number of catastrophic SCIs will occur each year. Mueller reported 116 deaths from 1945 to 1994 that were attributable to cervical spine injuries in all levels of American football.<sup>4</sup> These injuries have the potential to be life changing events, with an enormous impact on the individual as well as their care-takers.

Of the 11,000 cases of traumatic SCI per year, 9% to 10% are related to sports.<sup>1,2,5</sup> Sports ranks as the fourth most common cause of SCI<sup>2,5</sup> and sporting accidents are second only to motor vehicle accidents as the leading cause of emergency department visits involving neck injuries.<sup>5-7</sup> Despite this, most injuries to the cervical spine remain minor; usually as ligament sprains, muscle strains, and soft-tissue contusions.<sup>8</sup>

## Anatomy

There are seven specialized vertebrae in the cervical spine. The vertebral bodies are comparatively small and slightly concave on their superior surface. Within the transverse processes are the foramen transversarium, which transmit passage of the vertebral arteries above the C7 level. The pedicles are oriented medially 15° to 40° and slightly cephalad. The inferior and superior articular surfaces of adjacent vertebrae form the facet joints, which are diarthrodial articulations and are oriented upward 30° to 45° from the horizontal. Secondary to this angulation of the facets, any rotation of the spine

---

David Chang, M.D., was a Chief Resident in the NYU Hospital for Joint Diseases Department of Orthopaedic Surgery, NYU Hospital for Joint Diseases, New York, New York. Joseph A. Bosco, III, M.D., is Assistant Professor of Orthopaedic Surgery, NYU School of Medicine and Attending in the Sports Medicine Service, NYU Hospital for Joint Diseases Department of Orthopaedic Surgery, New York, New York.

*Correspondence:* Joseph A. Bosco, M.D., Suite 8U, New York University Medical Center, 530 First Avenue, New York, New York 10016.

**Table 1** Cervical Spine Trauma Commonly Seen in Athletes

Condition	Mechanism	Pathology	Symptoms	Diagnosis and Treatment	Return to Sport
Transient Quadraplegia (TQ)	<ul style="list-style-type: none"> <li>• Axial loading</li> <li>• Hyperextension</li> </ul>	<ul style="list-style-type: none"> <li>• Spinal cord contusion and edema</li> </ul>	<ul style="list-style-type: none"> <li>• Motor and/or sensory, affecting two to four limbs</li> </ul>	<ul style="list-style-type: none"> <li>• MRI</li> <li>• Steroids</li> </ul>	<ul style="list-style-type: none"> <li>• Once symptoms resolve, if there is no congenital spinal stenosis on MRI</li> </ul>
Stingers Burners	<ul style="list-style-type: none"> <li>• Traction or compression of brachial plexus</li> </ul>	<ul style="list-style-type: none"> <li>• Brachial plexus</li> <li>• Neuropraxia</li> </ul>	<ul style="list-style-type: none"> <li>• Episode of upper extremity unilateral numbness, weakness, or burning pain</li> </ul>	<ul style="list-style-type: none"> <li>• Observation</li> <li>• For recurrent episodes, EMGs and MRI of brachial plexus</li> </ul>	<ul style="list-style-type: none"> <li>• When symptoms resolve</li> </ul>
Cervical herniated disc	<ul style="list-style-type: none"> <li>• Multiple episodes of axial loads or twisting injury to neck</li> </ul>	<ul style="list-style-type: none"> <li>• Herniated disc, "hard" or soft</li> </ul>	<ul style="list-style-type: none"> <li>• Radiculopathy in upper extremity</li> <li>• Myelopathy</li> </ul>	<ul style="list-style-type: none"> <li>• MRI</li> <li>• Indications for surgery: Myelopathy Persistent pain unresponsive to nonoperative treatment</li> </ul>	<ul style="list-style-type: none"> <li>• 1-level fusion, if asymptomatic</li> <li>• 2-3 levels of fusion, relative contraindication</li> <li>• More than 3 levels of fusion, absolute contraindication</li> </ul>
Cervical strain/sprain	<ul style="list-style-type: none"> <li>• Cervical loading or eccentric muscle contraction</li> </ul>	<ul style="list-style-type: none"> <li>• Ligament sprain</li> <li>• Muscle strain</li> </ul>	<ul style="list-style-type: none"> <li>• Neck pain</li> <li>• Radiculopathy</li> <li>• Tenderness and spasm</li> </ul>	<ul style="list-style-type: none"> <li>• Cervical collar</li> <li>• Flexion/extension radiographs once spasm has resolved.</li> <li>• If instability returns, may require fusion</li> </ul>	<ul style="list-style-type: none"> <li>• Asymptomatic and full-strength neck function restored</li> </ul>
Spear tackler's spine	<ul style="list-style-type: none"> <li>• Multiple episodes of cervical trauma with axial load</li> </ul>	<ul style="list-style-type: none"> <li>• Cervical stenosis</li> <li>• Loss of cervical lordosis</li> <li>• Cervical spondylosis</li> </ul>	<ul style="list-style-type: none"> <li>• Neck pain</li> <li>• Catastrophic cervical fractures</li> </ul>	<ul style="list-style-type: none"> <li>• Therapy to restore full ROM</li> </ul>	<ul style="list-style-type: none"> <li>• Controversial</li> <li>• May need to avoid contact sports</li> </ul>
Cervical stenosis	<ul style="list-style-type: none"> <li>• Multiple episodes of trauma</li> <li>• Congenital</li> </ul>	<ul style="list-style-type: none"> <li>• Narrowing of cervical canal by hypertrophy of ligaments and facet joints</li> <li>• Disc encroachment</li> </ul>	<ul style="list-style-type: none"> <li>• Upper extremity weakness</li> <li>• Paresthesias</li> <li>• Lower extremity myelopathy</li> </ul>	<ul style="list-style-type: none"> <li>• MRI demonstrating spinal cord contour deformation or obliteration of local CSF space</li> </ul>	<ul style="list-style-type: none"> <li>• If symptomatic or asymptomatic with TQ, contact sports should be avoided</li> </ul>

between C3 and C7 must be accompanied by a lateral tilt in the same direction. The joint capsules surrounding the facets are richly innervated by proprioceptive and pain receptors.<sup>9</sup> The laminae of the vertebrae blend into the lateral masses, which lie in the axial plane between the superior and inferior articular surfaces of the respective vertebra.<sup>9</sup> The uncinate processes are posterolateral projections from the superior endplate. Each segment of the subaxial spine allows for coupled rotation and lateral bending, due to the unique shape of the uncovertebral articulation and facet joints, which further increases the functional range of cervical motion.

The large range of motion (ROM) afforded by the cervical spine comes at the cost of a measure of stability, as the

cervical region has relatively little intrinsic bony stability and relies on ligamentous restraints to avoid excessive or pathologic mobility. The C1-C2 facets are oriented in the axial plane, which allows for left/right rotation. The upper cervical spine is especially critical to overall mobility, as approximately one-half of the flexion/extension arc is achieved by the atlanto-occipital articulation, and approximately 50% of neck rotation occurs between the atlas and axis.<sup>10</sup>

The primary static stabilizers of the neck include the anterior longitudinal ligament (ALL), intervertebral disc, posterior longitudinal ligament (PLL), ligamentum flavum, facet capsules, and interspinous and supraspinous ligaments. Important dynamic stabilizers consist of the

sternocleidomastoid, trapezius, strap muscles (sternohyoid, sternothyroid, thyrohyoid, and the omohyoid), and paraspinal muscles. The muscular envelope functions as a dynamic splint and protects the cervical spine during ROM, whereas the ligamentous structures act as a checkrein, limiting motion at the end points.<sup>8</sup>

In the subaxial cervical spine, the spinal cord occupies approximately 50% of the canal. The spinal cord averages 8 mm to 9 mm in the midsagittal diameter. There are eight cervical nerve roots that exit directly above the corresponding pedicles. These nerves course horizontally to exit the neural foramina posterior to the vertebral artery.

### Prehospital Care

Prehospital care begins in the field. The involved caretakers, EMTs (emergency medical technicians), and athletic trainers, are pivotal and must be experienced in recognizing and addressing the cervical spine injured patient. Knowing the correct protocols of CPR (cardiopulmonary resuscitation) and ACLS (advanced cardiac life support) is paramount, as well as having and applying the correct equipment. Attention to changes in the person's ABCs (airway, breathing and circulation), neurological status, and level of consciousness all factor critically into initial management.

Cervical spine injuries may or may not have immediately observable neurological sequelae. Athletes who display spasm, tenderness, or loss of active range of motion (AROM) should be suspected of having significant cervical spine trauma and treated accordingly.<sup>11</sup> Additional red flags include severe neck pain, rigid cervical spasm, persistent athlete apprehension, and severe cervical tenderness.<sup>12</sup> All unconscious athletes in a situation that may have included a collision or a fall and conscious athletes with any sign or symptoms that suggest cervical spine trauma must be treated as if a cervical spine injury has occurred.<sup>11</sup> Spinal immobilization is needed when moving these patients; the head and trunk are moved as a unit. Passive range of motion (PROM) is never performed until a cervical spine injury has been ruled out.

History obtained from witnesses may be vital. The most worrisome injury or mechanism is one of axial loading with the neck flexed or hyper-extended. These circumstances can cause pinching of the spinal cord, resulting in spinal cord neurapraxia.<sup>13</sup> A history of spear tackling, which is using the helmet/head as the point of impact when tackling an individual, is worrisome, because the normal protective effect of cervical lordosis is lost upon impact. This can result in severe, acute neurological injury and chronic bony abnormalities of the cervical spine.<sup>13</sup>

With regard to football and hockey, the shoulder pads and helmet should stay on during transportation. The face shield is removed for airway management. The airway is cleared using only jaw thrust maneuvers, as opposed to performing cervical spine extension. The single reason to reposition the head with cervical spine extension is when

the risk of asphyxiation is greater than the risk of cervical injury or when the helmet prevents cervical immobilization. The overall goal of treatment, beginning with prehospital care, is to protect uninjured neural tissue, maximize recovery of injured tissues, and optimize conditions for the spinal column to heal in a satisfactory alignment.

### Imaging

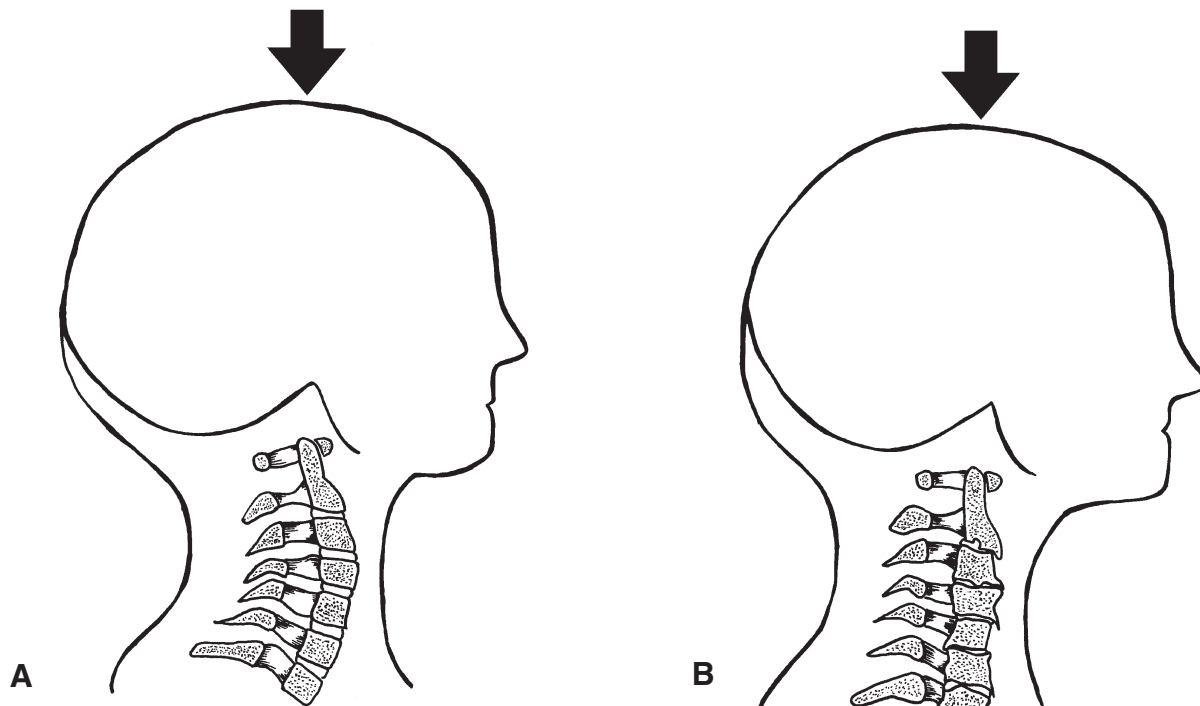
The American College of Surgeons recommends in its ATLS (Advanced Trauma Life Support) guidelines that all patients with a traumatic injury above the clavicle have a cervical spine radiograph. However, the National Emergency X-Ray Use Study (NEXUS) found that patients who had no midline cervical tenderness, no focal neurological deficits, normal alertness, no intoxication, and no painful distracting injuries had a low probability of cervical spine injury. Therefore, fully conscious athletes who have cervical trauma can be cleared without radiographic studies provided the above criteria are met.<sup>14</sup>

"The Canadian C-Spine Rule for Radiography in Alert and Stable Trauma Patients" is another prospective cohort study investigating this issue.<sup>15</sup> This study found a low risk of cervical spine injury if patients had no limitation of cervical rotation (45° in either direction), none of the three risk factors that mandated radiographic studies (age greater than 65, dangerous mechanism of injury, or upper extremity paresthesias), and one of the following was true for the patient: (1) had a simple rear-end motor vehicle collision, (2) was in a sitting position in the emergency department, (3) was ambulatory at any time after the injury, (4) had a delayed onset of neck pain, or (5) there was an absence of midline tenderness.

A comparison study between the above two mentioned investigations (NEXUS and Canadian C-Spine Rule) showed the Canadian study to have superior sensitivity and specificity.<sup>16</sup> However, one should keep in mind that both studies focused on developing a set of criteria for use in an emergency department and not on the athletic field.

A complete radiographic cervical spine series includes lateral cervical spine, AP, and open mouth views. If the patient is neurologically stable, flexion/extension lateral views may be obtained to demonstrate instability. A contrast-enhanced computed tomography (CT) scan or magnetic resonance imaging (MRI) is used to evaluate the contents of the spinal canal. Holmes and coworkers performed a study that demonstrated MRI identified 100% of the cervical ligamentous and SCIs in patients being evaluated for cervical spine trauma.<sup>17</sup>

Webb and associates described several radiographic signs that were found to be indicative of cervical instability: interspinous widening, vertebral subluxation, vertebral compression fracture, and loss of cervical lordosis.<sup>18</sup> Herkowitz and Rothman reported six patients with cervical instability on follow-up after no instability was found on presentation.<sup>19</sup> The false negative work-up was thought to result from the



**Figure 1** A, Demonstrates normal cervical spine. Note lordosis. B, Demonstrates typical findings in Spear tackler's spine. Note the loss of lordosis, disc space narrowing, and osteophyte formation. These preclude the spine from absorbing axial loads. Arrows denote axial load.

presence of muscle spasm that masked the initial instability on radiographs. The authors recommended maintaining immobilization until the resolution of this initial muscle spasm and serial follow-up radiographs.

### Spear Tackler's Spine

Axial loading of the spine is a common mechanism of severe spinal cord injury during athletics (Fig. 1).<sup>20</sup> When the normal cervical lordosis is lost, an impact to the top of the head is able to transmit extreme axial forces that can result in severe bony and neurologic injury. As mentioned above, spear tackling is a method of tackling in football that involves using the crown of the head as the initial point of contact. Spear tackler's spine is a constellation of radiographic and clinical parameters that includes the use of spear tackling techniques, with radiographic development of cervical stenosis, straightening or reversal of the normal cervical lordotic curve, and posttraumatic bony changes (spondylosis).<sup>20</sup> Athletes may also have a developmental narrowing of the spinal canal. In 1975, football rules were changed to ban the use of spear-tackling techniques. Torg and colleagues went so far as to say that spear tackler's spine is an absolute contraindication to participation in contact/collision sports.<sup>21</sup>

### Cervical Spinal Stenosis

Cervical spinal stenosis is often diagnosed after a spinal injury has occurred. Clinically, patients will report symptoms of weakness or paresthesias in more than one extremity and rarely neck pain. It is possible to think of stenosis as a risk

factor for, or having an association with, the subsequently described injuries (e.g., transient quadriplegia). Stenosis is a controversial entity, as there is no consensus or quantitative definition. Measurement of the midsagittal canal can vary by radiographic technique. Normal values are considered to be between 14 mm and 23 mm, with a measurement of less than 13 mm defined as stenosis.<sup>22</sup> These numbers are also argued as unreliable, however, because of the magnification error from plain films.

The Torg-Pavlov ratio hoped to account for the magnification error associated with plain radiographic films. The ratio is the midsagittal diameter of the spinal canal (measured from the midpoint of the posterior vertebral body to the nearest point on the spinolaminar line) to the anteroposterior diameter of the corresponding vertebral body. A ratio of less than 0.8 is considered canal stenosis.<sup>23</sup> A ratio of 1.0 is normal. This diametral proportion is highly sensitive (greater than 90%; few false negatives)<sup>24</sup> but has low positive predictive value (13%; large number of false positives).<sup>25</sup> Herzog and coworkers found that many athletes have a larger than normal vertebral body width, which caused the Torg ratio to be misleading.<sup>25</sup> Meanwhile, Blackley and associates demonstrated that measurement of the spinal canal by plain film radiographs is not reliable and that ratios cannot correct the error.<sup>26</sup> These and other authors<sup>27,28</sup> argue that radiographs do not take into account the size and shape of the spinal cord, the functional reserve of the spinal canal, the presence of a disc herniation via Torg's method, nor the unreliability of the Torg ratio in different clinical settings.

Although there seems to be a relationship between a low Torg ratio and spinal injury, it does not necessarily predispose athletes to an initial injury.<sup>22</sup> Athletes with a low Torg ratio are, however, at an elevated risk for recurrent injuries such as stingers and transient quadriplegia.<sup>29</sup> It has been proposed that a Torg ratio of 0.70 is a better threshold for determining significant stenosis.<sup>29</sup>

With all of this unreliability, cervical spinal stenosis is probably best described as a narrowing of the spinal canal with congenital and acquired forms. The congenital form describes someone born with a smaller diameter canal than the general population or a structural anomaly such as a posterior bony bar. An acquired form of stenosis may be caused by enlargement of facet joints, ligaments, or encroachment of the disc. Cantu acknowledges that nonosseous structures can create stenosis and, therefore, a loss of CSF surrounding the cord or compression of the cord, as revealed by contrast-enhanced CT, MRI, or myelography, is a more accurate assessment of stenosis.<sup>30</sup> This raises the concept of functional stenosis, which can be defined as a spinal cord contour deformation or obliteration of local cerebrospinal fluid space. Cantu has gone so far as to recommend that athletes with this functional stenosis who have an episode of transient quadriplegia should be prohibited from participation in contact sports.<sup>30</sup>

### Transient Quadriplegia

Transient weakness of the extremities can be referred to by several names: transient quadriplegia (TQ) or transient quadriplegia, cervical cord neurapraxia (CCN), and spinal cord concussion. Athletes will report symptoms that include varying degrees of sensory or motor disturbances affecting two to four limbs. The sensory disturbances are burning pain to loss of sensation. The motor deficits usually affect bilateral upper or lower extremities. Athletes will report symptoms of weakness to complete paralysis. Duration of these symptoms and signs is usually relatively short-lasting, 10 to 15 minutes, but residual symptoms can persist for 36 to 48 hours.<sup>31</sup>

Extended signs and symptoms following a cervical spinal cord injury would probably not be classified as neurapraxia. The incidence in college football is approximately 1.3/10K,<sup>23</sup> but is common in other collision/contact sports, such as hockey, wrestling, boxing, and basketball.<sup>31</sup> This clinical entity may be associated with developmental cervical stenosis, kyphosis, presence of a congenital fusion, cervical instability, and/or a disc protrusion or herniation.

A key element in diagnostic evaluation is imaging, the evaluation of which will affect return to play decisions. The goal of the initial radiographic examination is to determine the integrity of the spinal elements, typically assessed by plain radiographs. With extension or flexion of the cervical spine, the AP diameter can be decreased by as much as 2 mm.<sup>31</sup> The cervical spinal cord and dura accommodate a wider range of spinal motion without injury through infold-

ing of redundant neural tissue as well as elastic deformation of neural tissue. The infolding of the laminar ligaments during hyperextension can reduce canal diameter by as much as 30%.<sup>31</sup> With spine flexion, the spinal canal dimensions widen; however, the neural contents, including the spinal cord and nerve roots, are maximally stretched and tightened. With spine extension, the spinal cord and nerve roots are slackened, but the spinal canal is narrowed.

The pathologic mechanism of injury is usually cervical hyperextension or axial loading of the neck while in flexion or extension. The "pincher" mechanism occurs when the cervical canal is narrowed by the movement of one vertebra on top of another during extreme flexion to hyperextension.<sup>32</sup> The cord may be compressed between the posteroinferior portion of the vertebral body above and the anterosuperior lamina of the vertebra below. The hyperextension mechanism results in spinal cord injury, primarily by narrowing the central spinal canal. Hyperextension causes infolding of the ligamentum flavum, which can result in a transient physiologic stenosis of the central canal, even in the absence of true spinal stenosis. However, in the presence of fixed spinal stenosis, the spinal cord is at greater risk of a direct compressive injury or injury secondary to vascular insult.

The axial load mechanism occurs when the cervical spine is slightly flexed (i.e., straightening the cervical lordosis), followed by direct impact of the crown of the helmet or head with an immovable object, such as the ground or another player. This action can result in two possible injuries. In the presence of a central disc herniation or posterior bony bar, transient compression of the anterior cord and anterior spinal artery may occur as the cord is stretched over these fixed structures, causing both direct and indirect cord compression and cord ischemia. The second type of injury results through minimization of the shock-absorbing capacity of the cervical spine, as it acts like a segmented column. The momentum of the body against a fixed cervical spine produces a progressive breakdown of the passive stabilizers, potentially resulting in a fracture-dislocation. Despite which mechanism of injury is reported, the neurapraxia is thought to be caused by a physiologic conduction block that ends in peripheral nerve axon dysfunction without anatomic disruption.<sup>31</sup>

Torg and colleagues studied 45 athletes who suffered a transient quadriplegic episode. Forty-two of these athletes had a Torg ratio less than 0.80. In their study, it was concluded that the risk of recurrent transient injury increases with decreasing Torg ratios.<sup>24</sup> In a later study of 110 athletes with TQ/CCN, Torg and coworkers<sup>33</sup> found that (1) 56% of athletes returning to competition sustained at least one additional episode of TQ/CCN; (2) no athlete developed a permanent neurologic injury even though the number of recurrent episodes of TQ/CCN ranged up to 25; and (3) direct assessment of the spinal canal and spinal cord reportedly revealed a significant correlation between spinal stenosis and the development of recurrent TQ/CCN.

While there may be a greater than 50% chance that an athlete will sustain another episode of TQ/CCN after returning to full competition following the initial episode, the reported absence of risk of developing a permanent spinal cord injury after a subsequent episode of TQ/CCN is less certain. Finally, if the development of spinal stenosis is assumed to be, in part, a degenerative process resulting from chronic, repetitive overload to the cervical spine, even in the absence of permanent neurologic deficit, long-term quality of life issues may arise as a result of pain caused by return-to-play recommendations. Though TQ/CCN may be a benign entity, all patients should undergo a routine radiographic and MRI examination. Patients with uncomplicated TQ/CCN may be advised that they can return to contact activities without increased risk of permanent neurologic injury. However, since the overall recurrence rate of 56% is related to the degree of cervical canal narrowing, patients can be counseled regarding the risk of recurrence using the following return-to-play recommendations<sup>32,34</sup>:

- Asymptomatic patients with a canal/vertebral body ratio of 0.8 or less: no contraindication;
- Patients with a ratio of 0.8 or less who have had one CCN episode: relative contraindication;
- Patients with CCN episodes and degenerative changes and/or intervertebral disk disease: relative contraindication;
- Patients with a CCN episode and MRI indication of cord defect or edema: relative to absolute contraindication; and,
- Patients with a CCN episode, ligamentous instability, neurologic symptoms lasting more than 36 hours, and/or multiple episodes: absolute contraindication.

## Stingers

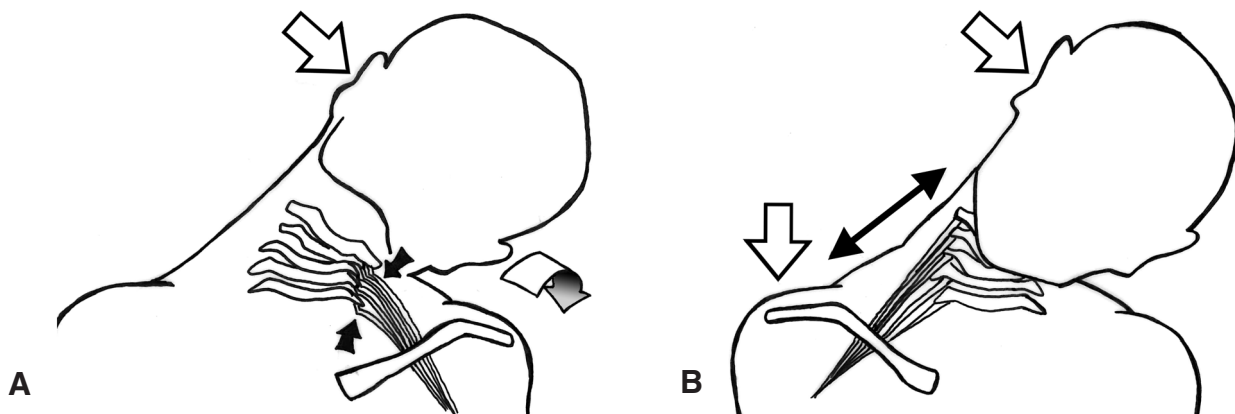
Stingers are defined as a temporary episode of unilateral upper extremity burning dysesthesia with or without motor weakness. Bilateral involvement suggests a cervical spinal

cord injury. The lower extremity is never affected. The central cord syndrome “burning hands” is often misdiagnosed as a stinger. The incidence may occur in as many as 50% of athletes involved in contact/collision sports.<sup>35,36</sup> Stingers are probably the most common yet least understood peripheral nerve injury occurring in sports. Most stingers are probably not reported by athletes, as their effect can be viewed as insignificant. It is estimated that stingers will occur at least once during the career of more than 50% of athletes in contact sports.<sup>24</sup> The usual levels involved are the biceps (C5-6), deltoids (C5), and spinati muscles (C5-6), the most common levels being C5 and C6. The duration of the symptoms is seconds to minutes, but symptoms and signs, particularly, weakness, may persist for as long as several weeks.<sup>2,37,38</sup>

There are two different pathologic mechanisms of injury: traction and compression (Fig. 2). Traction (stretch) injury to the brachial plexus can occur when the neck is flexed laterally and the contralateral shoulder is depressed. This mechanism occurs more commonly in the younger athlete without cervical stenosis or degenerative changes of the cervical spine. The Spurling test is often negative. Extension of the cervical spine can result in nerve root compression within the neural foramina during extreme lateral flexion of the neck.<sup>1</sup> These are extension-compression burners and occur in a more mature athletic population (college/professional). They are generally associated with preexisting radiologic evidence of cervical disc disease or arthritic changes. This subset of patients usually exhibits a positive Spurling test.

Jackson and Lohr devised a clinical grading system for stingers: grade I, motor and sensory function usually return after a few minutes; grade II, loss of muscle strength persists after three weeks, but resolves by six months; and grade III, motor and sensory deficits last longer than one year.<sup>39</sup>

The necessity of imaging or electrodiagnostics depends on the persistence of symptoms and signs as well as the number of stingers the athlete has sustained, which often is underreported. Imaging of the cervical spine reveals ana-



**Figure 2** A, Traction mechanism of stingers. Note the traction on the brachial plexus. B, Compression mechanism of stingers. Open arrows denote direction of force.

tomic abnormalities that may contribute to the development of the stinger, whereas electrodiagnostic testing assesses neurophysiologic function. Usually, there is no indication for such studies if an athlete fully recovers within seconds to a minute when experiencing a first episode. Testing, however, is indicated for recurrent episodes or persistent symptoms.

Radiographs may reveal degenerative changes, neuroforaminal stenosis due to uncovertebral or zygoapophyseal joint arthropathy, hypermobility, instability, and frequently, postural dysfunction, as evidenced by loss of cervical lordosis. The degenerative processes that result in these lateral canal changes also contribute to central canal stenosis; therefore, it is not uncommon to observe central and foraminal stenosis in athletes who have sustained a stinger. However, the central stenosis is probably an incidental finding and does not contribute to the pathomechanical or clinical patterns observed in these athletes. MRI may corroborate neuroforaminal stenosis and disc abnormalities, including herniation and degenerative disc changes. Profound weakness, unremitting pain, or delayed recovery are indications for ordering an MRI.

Electromyography (EMG) evaluation is reasonable after two weeks post-injury or if weakness progressively worsens. The goals of EMG are to confirm cervical nerve root injury versus the less common brachial plexus injury, to quantify the degree of nerve injury (e.g., differentiate a neurapraxic root injury from axonopathy), to isolate a specific nerve root level, and to assist with planning appropriate rehabilitation and return to competition. EMG can be performed as early as 7 to 10 days following injury and is the most sensitive technique for evaluating axonal loss in the presence of continued clinical weakness. However, milder injuries may be difficult to recognize, because these injuries typically result in a relatively mild degree of axonal injury and a variable degree of neurapraxia.

It is thought that spinal stenosis might be a cause of stingers. Meyer and associates reported a 47% incidence of spinal stenosis in football players who suffered a stinger, compared to a 25% incidence of stenosis in asymptomatic players.<sup>40</sup> Athletes with a lower Torg ratio have been described in the literature as having a higher incidence of recurrent stingers.<sup>29</sup> According to Torg and Ramsey-Emrheim, recurrent stingers do not increase the risk of more serious neck injury.<sup>32</sup> In a study by Levitz and colleagues, 93% of football players with chronic stingers did demonstrate significant cervical disc disease or narrowing of the neural foramina on MRI.<sup>38</sup> It is conjectured that recurrent stingers are more likely to result in residual neurologic deficit, particularly weakness.

There is less disagreement with regard to return to play of athletes with stingers compared to transient quadripareisis. There are still no well established guidelines. That being said, athletes should be removed from competition while symptomatic.<sup>41</sup> An athlete with a first-time stinger can return to the field as soon as the symptoms have resolved.<sup>41</sup> Because of the noncatastrophic nature of this injury and

the relatively quick resolution of pain, the initial sideline examination is often an inadequate, cursory evaluation of hand grip strength. What is required is assessment of the cervical ROM and any local tenderness as well as a thorough neurologic examination. A myotomal motor exam must be performed. Symptoms as well as their status should be monitored before allowing an athlete back into competitive play; they include: resolved neck and arm pain, resolved dysesthesia, full pain-free range of neck motion, full pain-free upper extremity range of motion, normal strength on manual muscle testing, normal deep tendon reflexes, and a negative Spurling test.<sup>42</sup> As long as the physician ensures that all symptoms have resolved and that there is no other injury contributing to the symptoms, the athlete usually can return to play very quickly, often during the same game.

Although stingers are very common, they can be prevented by equipping athletes with properly fitted equipment. For example, in football, correctly fitted shoulder pads, instruction on correct blocking and tackling techniques, and wearing a cervical neck roll (which limits lateral neck flexion) may reduce the frequency of stingers. Neck collar use remains controversial, because no study regarding the efficacy of the collars in the prevention of stingers has been performed.

### **Herniation and Cervical Disc Disease**

Cervical disc injuries and herniations in the athlete are less common than lumbar disc injuries and usually affect older athletes. Disc herniation is an uncommon cause of neck pain in young athletes. Zmurko and colleagues and Albright and coworkers noted an increased incidence of cervical disc disease in high performance athletes participating in football and wrestling compared with the general population.<sup>8,43</sup> In contrast, Mundt and associates concluded that athletes participating in noncontact sports might actually be protected against the development of cervical or lumbar disc herniation.<sup>44</sup> The mechanism of this apparent protection was hypothesized to be due to improved muscular conditioning that protected the disc from pathologic stresses placed on the spine.

There are two types of disc disease: soft and hard. A soft disc refers to an acute process in which the nucleus pulposus herniates through the posterior annulus, resulting in signs and symptoms of cord or nerve root compression. Acute cervical disc disruptions that occur as a result of sports participation have been hypothesized to result from uncontrolled lateral bending of the neck.<sup>43</sup> Hard disc disease generally represents a more chronic degenerative process with a diminished disc height and the formation of marginal osteophytes.

The initial treatment of almost all herniated cervical discs in athletes is the same as in nonathletes: nonoperative. Rest, activity modification, NSAIDs (nonsteroidal anti-inflammatory drugs), immobilization, cervical traction, and therapeutic injections are modalities that can be implemented

prior to consideration of surgical treatment.<sup>8</sup> Only in the rare situation involving myelopathy or a progressive neurologic deficit should surgery be contemplated during the initial six to eight weeks of conservative management. As symptoms improve, gentle exercises can gradually be instituted, emphasizing isometric strengthening and cervical range of motion, followed by sport specific exercises and drills. Sports can be resumed when the athlete is asymptomatic and has regained full strength and mobility.<sup>8</sup>

Surgery is a reasonable consideration if symptoms of arm pain persist despite conservative measures. The cervical disc can be approached surgically from anterior or posterior. Some authors suggest that an athlete may achieve a quicker recovery following laminoforaminotomy without fusion (but no direct comparison study has been performed).<sup>44</sup>

Athletes undergoing nonoperative treatment may return to play when they are asymptomatic, have regained full strength, and ROM has returned to baseline. The postoperative athlete's return to play depends on the level and number of levels fused. A stable one-level spinal fusion at C3 or below is not a contraindication for contact or collision sports. Experts suggest that following a posterior disc procedure, athletes can return to play when they are asymptomatic and have regained full strength and mobility.<sup>44</sup> Following anterior discectomy and fusion up to two levels, return to play can be considered following successful fusion and rehabilitation. While asymptomatic athletes who have normal neurological function and a two- or three-level spinal fusion may be allowed to return to contact or collision sports, they are usually advised to avoid this type of sport, because the stresses at the vertebrae adjacent to the fusion may lead to degenerative changes. Patients with longer fusions are generally considered to be at risk for returning to contact sports. Lower level cervical fusions are at less risk when compared with more proximal cervical fusions, due to the ability of the fusion mass to distribute and absorb cervical stresses.<sup>45</sup> Fusions above C3 and those involving more than three spinal levels are an absolute contraindication to contact or collision sports.<sup>32</sup>

### Cervical Strains and Sprains

Cervical strains and sprains are among the most common sports-related neck injuries.<sup>8</sup> A strain involves injury to cervical muscles or musculotendinous junctions, whereas a sprain involves injury to the cervical ligaments. Often there is overlap between these injuries with components of muscle stretch, contusion, and ligament sprains coexisting as the result of a single traumatic event. Strains usually occur from eccentric contraction of the neck muscles that cause microscopic or gross tensile failure.<sup>8,13</sup> Muscles with high ratios of fast twitch fibers (type II) have been found to have a higher risk for strains.<sup>8,46</sup>

Radiographically, greater than 3.5 mm AP displacement on flexion-extension cervical spine views or 11° of rotation on AP radiographs indicate cervical ligamentous laxity.<sup>47</sup>

These findings are a contraindication to contact or collision sports participation.<sup>32</sup>

The initial treatment for strains and sprains is similar: rest; ice; NSAIDs; neck support, as needed; and gentle ROM exercises. Sprains usually take more time to heal. Ligament injuries can cause laxity, which increases athletes' risk of neurological injury. Anatomical studies have identified encapsulated mechanoreceptors in the cervical facets that allow proprioceptive information from the cervical spine.<sup>48</sup> Mechanoreceptors provide pain perception from the articulation and are theorized to play a significant role in protective muscular contraction in the response to unexpected external forces.

During the post-injury period, cervical immobilization and complete radiographic evaluation need to be performed. Aside from rest and pharmaceuticals, the cervical collar should be maintained until muscle spasm has subsided (often 7 to 10 days).<sup>8</sup> Adequate dynamic radiographs should be taken after the spasms have abated. If dynamic radiographs are negative, then the collar can be weaned and gentle ROM and isometric strengthening exercises can be instituted. Prolonged immobilization leads to atrophy and deconditioning of healthy muscle fibers and thus should be avoided.<sup>46</sup> As the patient improves clinically, functional and sports specific exercises are begun. Return to play is allowed when all symptoms of the cervical sprain or strain have resolved and full strength, range of motion, and sport specific neck function have been regained. An ongoing cervical conditioning program is recommended to minimize the risk of injury recurrence.<sup>8</sup>

The role of specific orthoses and formal physical therapy in preventing or decreasing the incidence of reinjury following sprain/strain is controversial. Sports specific orthoses, particularly in football, have been used empirically for many years, with the thought that they limit excessive motion and thus decrease the risk of injury. Hovis and Limbird demonstrated that commonly used cervical orthoses were competent in limiting hyperextension of the cervical spine, while allowing enough extension to prevent axial loading injuries.<sup>49</sup> However, these braces did not consistently limit lateral bending of the neck. In a prospective study by Borchegrevink and colleagues, no difference was found between patients with forced flexion-extension trauma who received immediate immobilization and physiotherapy and patients instructed to resume activities, as tolerated.<sup>50</sup>

### Special Populations

Athletes with particular conditions are deserving of special mention and include those diagnosed with Down syndrome, rheumatoid arthritis, odontoid anomalies, atlanto-occipital fusion, or Klippel-Feil syndrome. Down syndrome patients have a high incidence of atlanto-axial instability, reportedly up to 30%.<sup>13</sup> Twelve to 16% of Down syndrome patients who have such instability develop neurologic signs and symptoms.<sup>51</sup>

The Special Olympics impose a temporary restriction on select activities for Down syndrome participants until a lateral neck radiograph shows no C-1 instability. The American Academy of Pediatrics initially supported this requisite but, in 1995, reexamined its position based on a reevaluation of the initial data. Their revised position was that plain film radiographs were “of potential but unproven value in detecting patients at risk for developing spinal cord injury during sports participation.”<sup>52</sup> The controversy arises from the fact that some Down syndrome patients can initially have abnormal radiographs but normal follow-up radiographs. Conversely, some patients have normal radiographs that eventually become abnormal as they age.

The neurological manifestations of atlantoaxial instability include neck pain, gait disturbances, decreased cervical mobility, torticollis, incoordination, spasticity, hyperreflexia, and clonus. If any of these symptoms are present, the athlete should be further worked-up with an MRI prior to participation. Down syndrome patients with atlantoaxial instability should be restricted from certain Special Olympics’ sports, to include gymnastics, diving, the pentathlon, the butterfly swimming stroke, high jump, soccer, and neck stretching warm-ups, as well as from contact sports like football, wrestling, and rugby. Dorshimer and Kelly recommend that Down syndrome patients who have atlantoaxial instability and stable neurological symptoms have current radiographic studies before participating in any athletic event, including noncontact sports.<sup>13</sup>

Patients with rheumatoid arthritis are at increased risk for spinal cord injury in contact sports because of an increased incidence of cervical instability. Cervical subluxation can be found in 15% of rheumatoid patients within three years of diagnosis, and 17% of rheumatoid patients who have radiographic abnormalities have neurological symptoms.<sup>13</sup> Thus, the index of suspicion for atlantoaxial instability must be high when evaluating a patient with rheumatoid arthritis and activity related neck pain.

The congenital abnormalities of odontoid agenesis, odontoid hypoplasia, and os odontoideum are all contraindications to participate in contact sports. Atlanto-occipital fusion represents partial or complete fusion of the bony ring of the atlas to the occiput and is, as well, a contraindication to contact sports.

The Klippel-Feil anomaly refers to congenital fusion of two or more vertebrae, of which there are two groups.<sup>34</sup> Type I is a mass fusion between the cervical and upper thoracic vertebrae. Type II, represents a fusion over one or two interspaces. The more segments involved, the greater the loss of motion and the greater the stresses on adjacent normal segments. The ability of the cervical spine to absorb and dissipate loads is clearly diminished with long fusion masses. A type I lesion constitutes an absolute contraindication to participation in contact sports because of the marked alteration in spinal mechanics to potentially predispose the athlete to injury or degenerative changes. However, a type II

lesion, involving fusion of one or two interspaces at C3 and below, should present no contraindication to sports for an individual with full cervical ROM and an absence of occipital cervical anomalies, instability, disc disease, or degenerative changes.<sup>34</sup>

## Vascular Injury

Cervical vascular injury is often secondary to blunt neck trauma. Even though trauma usually results in a minor contusion, the event may cause cervical vascular structural damage. Blunt trauma to the carotid artery can cause a dissection, thrombus, or emboli—all of which can result in stroke. There have been cases of syncope, delayed neurological symptoms, even death from carotid artery trauma.<sup>53,54</sup> Otherwise, vascular injury is very rare and is most often seen in blunt trauma in football or neck holding maneuvers in the martial arts. Treatment includes anticoagulation, thrombolytic therapy, and possibly vascular surgery. The key to treating these patients is early recognition, prompt anticoagulation, and urgent consultation with a vascular surgeon.

## Conclusions

Severe cervical spine injuries in the athlete are not common; frequency of injury is related to injury severity. With regard to return to play criterion and evidence-based medicine, most data is level IV or V evidence, anecdotal, and controversial. This is especially true for transient quadriplegia/cervical cord neurapraxia associated with stenosis. A great deal of pressure from coaches, families, and the athletes may be expressed for returning to play as quickly as possible. Decisions by the physician to allow an athlete to return to play after a spinal injury should be made on a case by case basis. The decision should be based on the type of injury, persistence of symptoms, recurrence of injury, the sport played, and the amount of risk for future injury as regards that sport.<sup>41</sup> Conservative decisions may prove prudent. While there is no substantial objective evidence in the athletic population that recurrent concussive injury to the spinal cord results in permanent neurologic damage, due consideration must be given to the potential, particularly for the development of myelopathy if spinal stenosis is present. Ultimately, most authors would agree that the minimum criterion to be fulfilled is that the patient be symptom-free, have regained their baseline neck range of motion, and achieved nearly full strength.<sup>13</sup>

## References

1. Ghiselli G, Schaadt G, McAllister DR. On-the-field evaluation of an athlete with a head or neck injury. *Clin Sports Med.* 2003 Jul;22(3):445-65.
2. Maroon JC, Bailes JE. Athletes with cervical spine injury. *Spine.* 1996 Oct 1;21(19):2294-9.
3. Clarke KS. Epidemiology of athletic neck injury. *Clin Sports Med.* 1998 Jan;17(1):83-97.
4. Mueller FO. Fatalities from head and cervical spine injuries occurring in tackle football: 50 years’ experience. *Clin Sports*

- Med. 1998 Jan;17(1):169-82.
5. National Spinal Cord Injury Statistical Center. University of Alabama at Birmingham. 2004 NSCISC Annual Statistical Report, August 2004.
  6. Reid DC, Saboe L. Spine fractures in winter sports. *Sports Med.* 1989 Jun;7(6):393-9.
  7. Versteegen GJ, Kingma J, Meijler WJ, ten Duis HJ. Neck sprain not arising from car accidents: A retrospective study covering 25 years. *Eur Spine J.* 1998;7(3):201-5.
  8. Zmurko MG, Tannoury TY, Tannoury CA, Anderson DG. Cervical sprains, disc herniations, minor fractures, and other cervical injuries in the athlete. *Clin Sports Med.* 2003 Jul;22(3):513-21.
  9. An HS. Anatomy of the spine. In: An HS (ed): *Principles and Techniques of Spine Surgery*. Baltimore: Williams & Wilkins, 1998, pp. 1-31.
  10. Dvorak J, Schneider E, Saldinger P, Rahn B. Biomechanics of the craniocervical region: The alar and transverse ligaments. *J Orthop Res.* 1988;6(3):452-61.
  11. Kleiner DM. Inter-Association Task Force for Appropriate Care of the Spine-Injured Athlete. Prehospital care of the spine-injured athlete: Monograph summary. *Clin J Sport Med.* 2003 Jan;13(1):59-61.
  12. Haight RR, Shiple BJ. Sideline evaluation of neck pain: When is it time for transport? *Phys Sports Med.* 2001 Mar;29(3):8-15.
  13. Dorshimer GW, Kelly M. Cervical pain in the athlete: Common conditions and treatment. *Prim Care.* 2005 Mar;32(1):231-43.
  14. Hoffman JR, Mower WR, Wolfson AB, et al. Validity of a set of clinical criteria to rule out injury to the cervical spine in patients with blunt trauma. National Emergency X-Radiography Utilization Study Group. *N Engl J Med.* 2000 Jul;343(2):94-9.
  15. Stiell IG, Wells GA, Vandemheen KL, et al. The Canadian C-spine rule for radiography in alert and stable trauma patients. *JAMA.* 2001 Oct 17;286(15):1841-8.
  16. Stiell IG, Clement CM, McKnight RD, et al. The Canadian C-spine rule versus the NEXUS low-risk criteria in patients with trauma. *N Engl J Med.* 2003 Dec 25;349(26):2510-8.
  17. Holmes JF, Mirvis SE, Panacek EA, et al. Variability in computed tomography and magnetic resonance imaging in patients with cervical spine injuries. *J Trauma.* 2002 Sep;53(3):524-9; discussion 30.
  18. Webb JK, Broughton RB, McSweeney T, Park WM. Hidden flexion injury of the cervical spine. *J Bone Joint Surg Br.* 1976 Aug;58(3):322-7.
  19. Herkowitz HN, Rothman RH. Subacute instability of the cervical spine. *Spine.* 1984;9(4):348-57.
  20. Torg JS, Sennett B, Pavlov H, et al. Spear tackler's spine. An entity precluding participation in tackle football and collision activities that expose the cervical spine to axial energy inputs. *Am J Sports Med.* 1993 Sep-Oct;21(5):640-9.
  21. Torg JS, Ramsey-Emrhein JA. Management guidelines for participation in collision activities with congenital, developmental, or postinjury lesions involving the cervical spine. *Clin J Sport Med.* 1997 Oct;7(4):273-91.
  22. Breslow MJ, Rosen JE. Cervical spine injuries in football. *Bull Hosp Joint Dis.* 2000;59(4):201-10.
  23. Torg JS, Pavlov H, Genuario SE, et al. Neurapraxia of the cervical spinal cord with transient quadriplegia. *J Bone Joint Surg Am.* 1986 Dec;68(9):1354-70.
  24. Torg JS, Naranja RJ, Jr., Palov H, et al. The relationship of developmental narrowing of the cervical spinal canal to reversible and irreversible injury of the cervical spinal cord in football players. *J Bone Joint Surg Am.* 1996 Sep;78(9):1308-14.
  25. Herzog RJ, Wiens JJ, Dillingham MF, Sontag MJ. Normal cervical spine morphometry and cervical spinal stenosis in asymptomatic professional football players. Plain film radiography, multiplanar computed tomography, and magnetic resonance imaging. *Spine.* 1991 Jun;16(6 Suppl):S178-86.
  26. Blackley HR, Plank LD, Robertson PA. Determining the sagittal dimensions of the canal of the cervical spine. The reliability of ratios of anatomical measurements. *J Bone Joint Surg Br.* 1999 Jan;81(1):110-2.
  27. Lim JK, Wong HK. Variation of the cervical spinal Torg ratio with gender and ethnicity. *Spine J.* 2004 Jul-Aug;4(4):396-401.
  28. Prasad SS, O'Malley M, Caplan M, et al. MRI measurements of the cervical spine and their correlation to Pavlov's ratio. *Spine.* 2003 Jun;28(12):1263-8.
  29. Castro FP, Jr, Ricciardi J, Brunet ME, et al. Stingers, the Torg ratio, and the cervical spine. *Am J Sports Med.* 1997 Sep-Oct;25(5):603-8.
  30. Cantu RC. The cervical spinal stenosis controversy. *Clin Sports Med* 1998;17(1):121-6.
  31. Allen CR, Kang JD. Transient quadriparesis in the athlete. *Clin Sports Med.* 2002 Jan;21(1):15-27.
  32. Torg J, Ramsey-Emrhein J. Cervical spine and brachial plexus injuries: Return-to-play recommendations. *Phys Sportsmed.* 1997 Jul;25(7):3-10.
  33. Torg JS, Corcoran TA, Thibault LE, et al. Cervical cord neurapraxia: Classification, pathomechanics, morbidity, and management guidelines. *J Neurosurg.* 1997 Dec;87(6):843-50.
  34. Torg JS, Ramsey-Emrhein JA. Management guidelines for participation in collision activities with congenital, developmental, or post-injury lesions involving the cervical spine. *Clin Sports Med.* 1997 Jul;16(3):501-30.
  35. Clancy WG Jr, Brand RL, Bergfield JA. Upper trunk brachial plexus injuries in contact sports. *Am J Sports Med.* 1977 Sep-Oct;5(5):209-16.
  36. Cantu RC. Stingers, transient quadriplegia, and cervical spinal stenosis: Return to play criteria. *Med Sci Sports Exerc.* 1997 Jul;29(7 Suppl):S233-5.
  37. Markey KL, Di Benedetto M, Curl WW. Upper trunk brachial plexopathy. The stinger syndrome. *Am J Sports Med.* 1993 Sep-Oct;21(5):650-5.
  38. Levitz CL, Reilly PJ, Torg JS. The pathomechanics of chronic, recurrent cervical nerve root neurapraxia. The chronic burner syndrome. *Am J Sports Med.* 1997 Jan-Feb;25(1):73-6.
  39. Jackson DW, Lohr FT. Cervical spine injuries. *Clin Sports Med.* 1986 Apr;5(2):373-86.
  40. Meyer SA, Schulte KR, Callaghan JJ, et al. Cervical spinal stenosis and stingers in collegiate football players. *Am J Sports Med.* 1994 Sep-Oct;22(2):158-66.
  41. Sanders AK, Boggess BR, Koenig SJ, Toth AP. Medico-legal issues in sports medicine. *Clin Orthop Relat Res.* 2005 Apr;(433):38-49.

42. Nissen SJ, Laskowski ER, Rizzo TD. Burner syndrome: Recognition and rehabilitation. *Phys Sportsmed*. 1996 Jun;24(6):57-70.
43. Albright JP, Moses JM, Feldick HG, et al. Nonfatal cervical spine injuries in interscholastic football. *JAMA*. 1976 Sep 13;236(11):1243-5.
44. Mundt DJ, Kelsey JL, Golden AL, et al. An epidemiologic study of sports and weight lifting as possible risk factors for herniated lumbar and cervical discs. The Northeast Collaborative Group on Low Back Pain. *Am J Sports Med*. 1993 Nov-Dec;21(6):854-60.
45. Watkins RG. Neck injuries in football players. *Clin Sports Med*. 1986 Apr;5(2):215-46.
46. Jarvinen TA, Kaariainen M, Jarvinen M, Kalimo H. Muscle strain injuries. *Curr Opin Rheumatol* 2000 Mar;12(2):155-61.
47. White AA 3rd, Johnson RM, Panjabi MM, Southwick WO. Biomechanical analysis of clinical stability in the cervical spine. *Clin Orthop Relat Res*. 1975;(109):85-96.
48. McLain RF. Mechanoreceptor endings in human cervical facet joints. *Spine*. 1994 Mar 1;19(5):495-501.
49. Hovis WD, Limbird TJ. An evaluation of cervical orthoses in limiting hyperextension and lateral flexion in football. *Med Sci Sports Exerc*. 1994 Jul;26(7):872-6.
50. Borchgrevink GE, Kaasa A, McDonagh D, et al. Acute treatment of whiplash neck sprain injuries. A randomized trial of treatment during the first 14 days after a car accident. *Spine*. 1998 Jan 1;23(1):25-31.
51. Winell J, Burke SW. Sports participation of children with Down syndrome. *Orthop Clin North Am*. 2003 Jul;34(3):439-43.
52. [Anonymous] Atlantoaxial instability in Down syndrome: Subject review. American Academy of Pediatrics Committee on Sports Medicine and Fitness. *Pediatrics*. 1995 Jul;96(1 Pt 1):151-4, 153.
53. Carr S, Troop B, Hurley J, Pennell R. Blunt-trauma carotid artery injury: Mild symptoms may disguise serious trouble. *Phys Sportsmed*. 1996 Feb;24(2):10-6.
54. McCarron MO, Patterson J, Duncan R. Stroke without dissection from a neck holding manoeuvre in martial arts. *Br J Sports Med*. 1997 Dec;31(4):346-7.